

Nursing Management of Patients with Arrhythmia



Kang young ae, CNS
Cardiovascular surgery intensive care unit
ASAN medical center


Arrhythmia

- Abnormality in the heart rhythm or heart beat pattern
; too fast, too slowly, extra beat, skip a beat, or beat irregularly
- d/t change of ion current
- Cause the heart to pump improperly
- Completely harmless or life-threatening

Heart cell

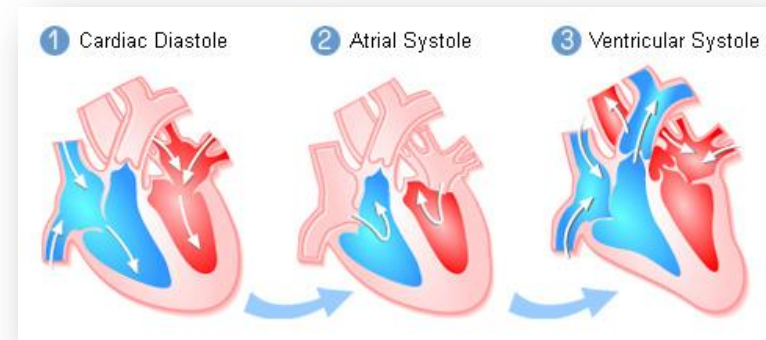
- **Electrical cells**

- * Specialized cell which conducted electrical impulses
- * **Start and transmit electrical activity** in the heart

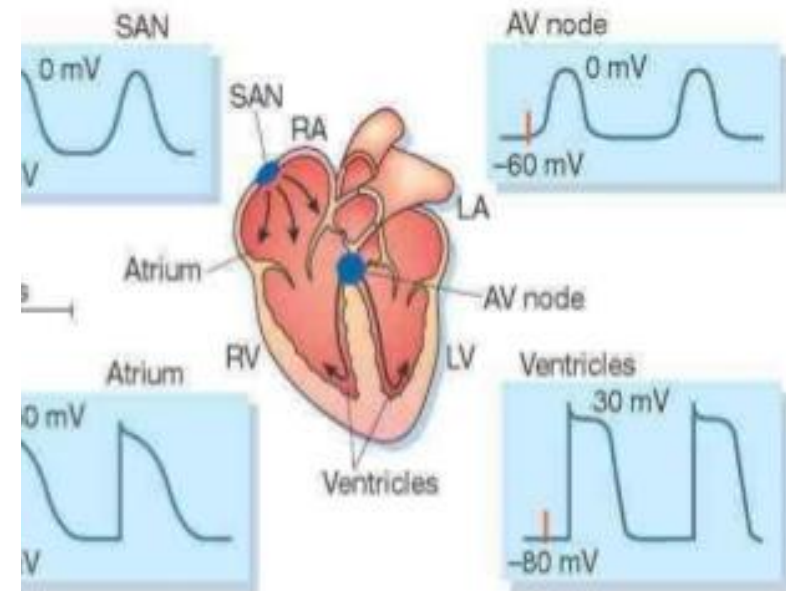
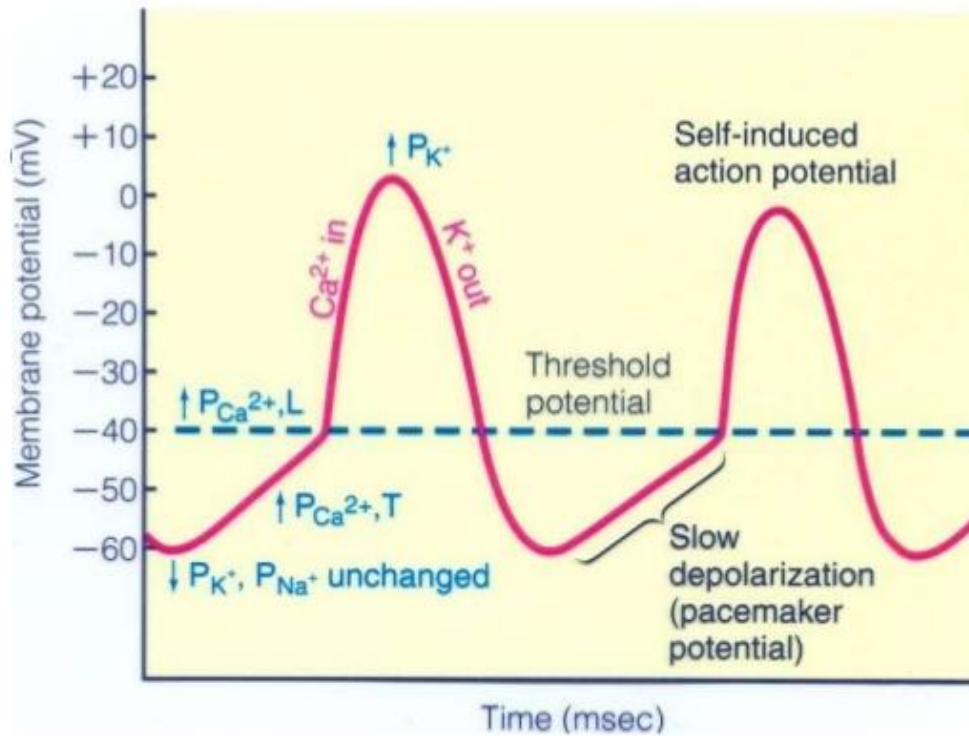


- **Mechanical cells**

- * Cells which make up bulk musculature in the heart
- * **Contract** in response to stimuli from the electrical cell



Action potential curve

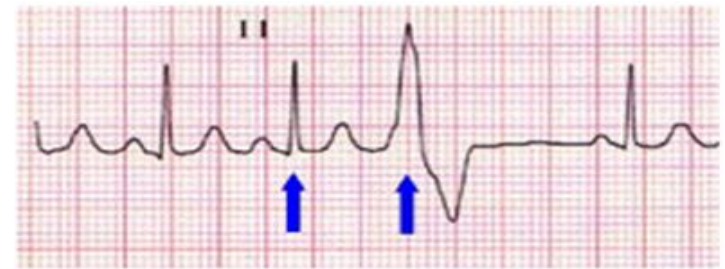


Mechanism of arrhythmia(1) Automaticity

비정상적인 세포의 자발적인 탈분극이 증가되어 자동능이 증가

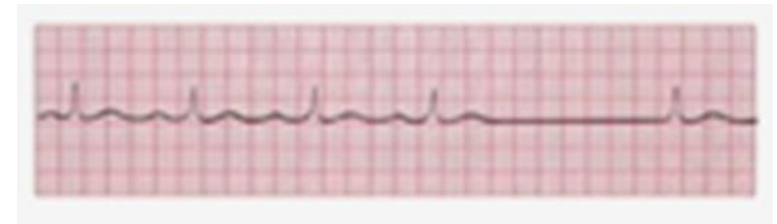* Ectopic beat or premature beat:

SA node 이외의 부위에서 비정상적으로 자동능이 증가하여 전기 자극 형성



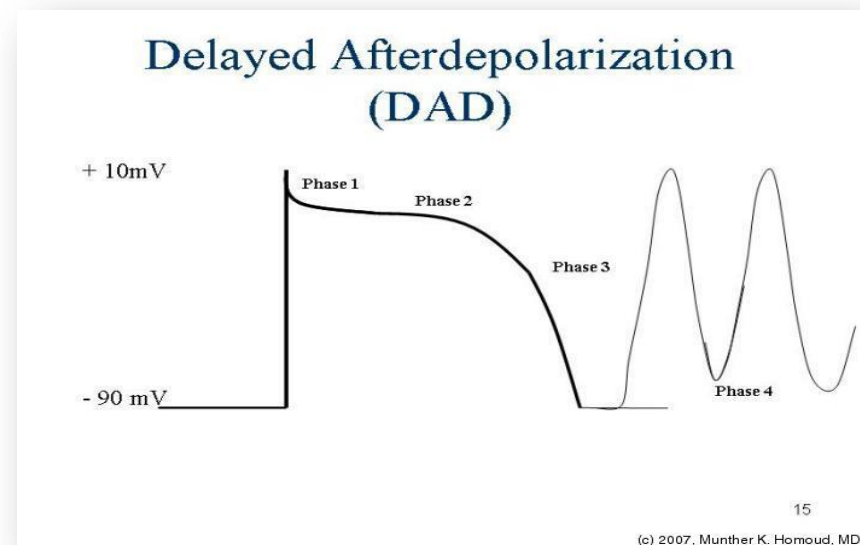
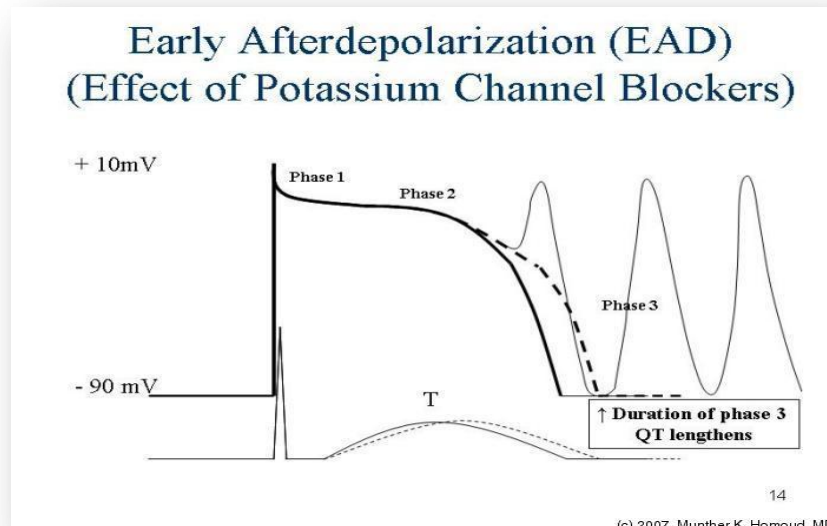
* Escaped beat :

SA node의 기능 부전으로 인해 SA node이하 부위에서 자극 형성



Mechanism of arrhythmia(2) Trigger activity

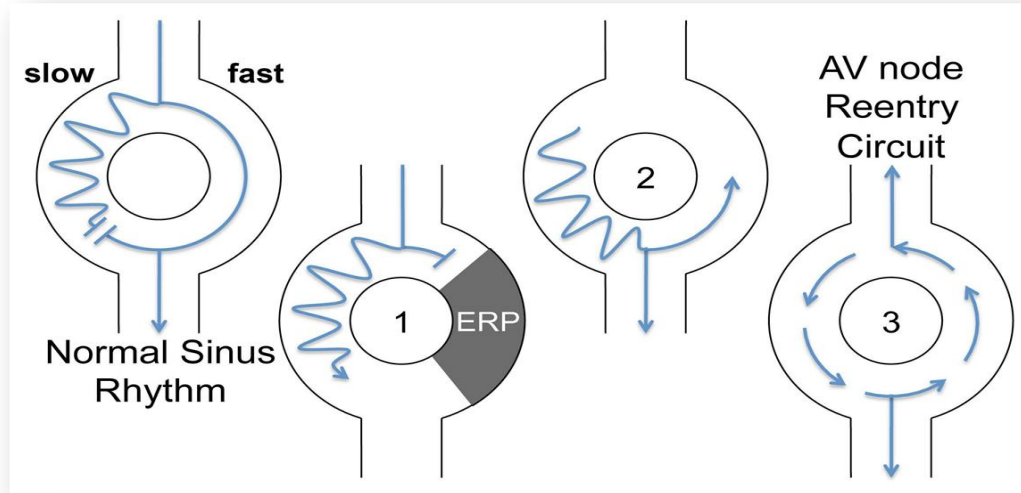
심근의 활동전위에서 재분극 시작 후 발생하는 후탈분극에 의해 세포가 다시 탈분극



Mechanism of arrhythmia(3) Reentry

전기적 특성이 다른 dual pathway가 하나의 회로를 형성한 조직에 조기 박동이 도달할 때 발생

대부분 빈맥성 부정맥의 원인



Diagnostic test

Non-invasive arrhythmia assessment is the critical first step

to arrive at a definitive diagnosis

- Electrocardiography
 - : Basic diagnostic test of arrhythmia or baseline EKG abnormalities
 - Easily accessible BUT artifact
 - Obscuration of electrical data from body surface
- Holter monitor
 - : 24 or 48 h evaluation with timestamps and event markers

Diagnostic test

- In-hospital telemetry
 - : Multi-channel, real-time monitoring
 - Technology allows patients to be ambulatory
 - Correlation of symptoms with arrhythmia
- Exercise test
 - : Reproduce activity so that arrhythmia may be provoked in patients with symptoms upon exercise
- Cardiac imaging, electrophysiologic test

Approach to patients with arrhythmia

- **History and ECG** are pivotal in directing the diagnostic workup and therapy
- From asymptomatic to life-threatening ECG abnormality
- Review of system
 - : Palpitation, syncope
- Physical examination
 - : Cardiopulmonary disease, thyroid disease
- Presence of structure heart disease and prior myocardial infarction

Treatment of arrhythmia

- Antiarrhythmic drug therapy

- : Structural similarity of target ion channel

- Regional difference in the level of expression of channels and transporters

- Catheter ablation

- : Critical anatomic region of abnormal impulse generation or propagation

- Destruction of critical region using radio-frequency or cryoablation

- Device therapy

- : Permanent pacemaker, internal cardioverter defibrillator (ICD) implantation

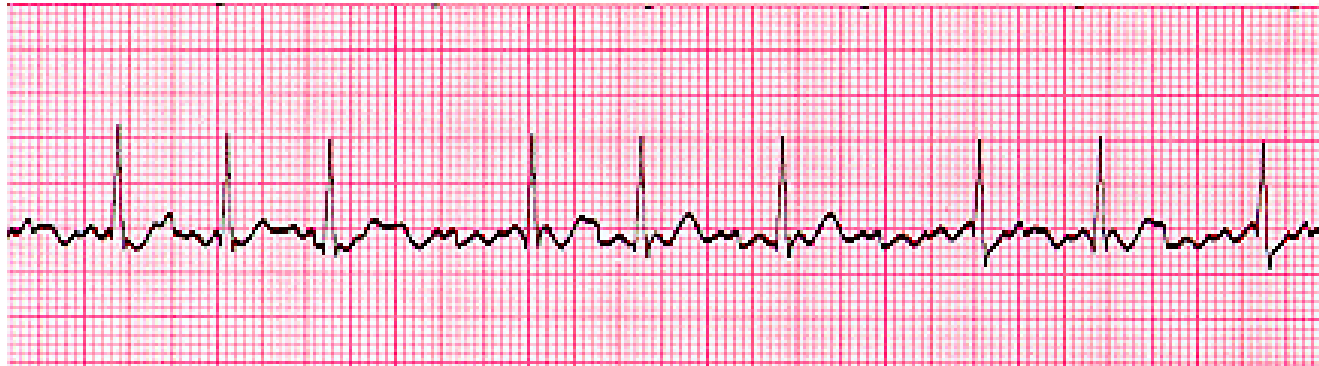CASE 1

63Y/M

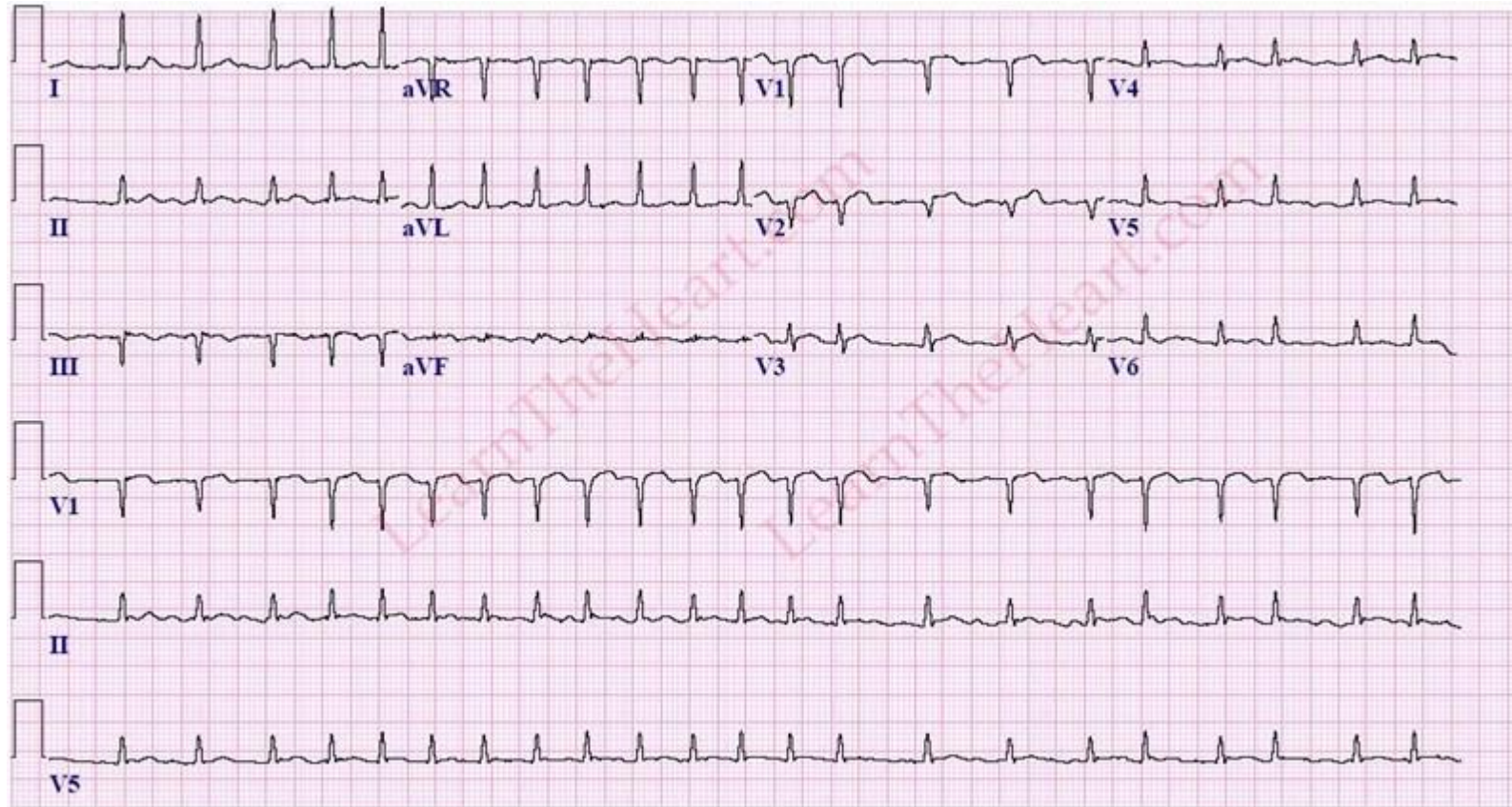
2~3 개월 전부터 시작된 심계항진으로 내원

고혈압, 당뇨는 없고,

최근 검진 시 촬영한 관상동맥 CT에서 심각한 관상동맥 질환은 없음



ECG



25mm/s 10mm/mV 40Hz 005C 12SL 254 CID: 22

EID: Unconfirmed EDT: ORDER:

Atrial fibrillation

- Multifocal ectopic pacemaker
 - P wave(f 파) : 300-600bpm
 - Rhythm : 방실전도 차단으로 심실로 매우 불규칙하게 전도(irregularly irregular)
 - QRS complex : 정상
 - Paroxysmal AF : 7일 이하로 지속되다가 저절로 없어짐
- Persistent AF : 7일 이상 지속
- Long-standing persistent AF : 비가역적 상태로 치료가 불가능한 상태

Management of atrial fibrillation

- 뇌졸중 예방, 삶의 질 개선을 포함한 증상 완화, 입원 및 심혈관 이환율과 사망률 감소

- **Rate control**

 - : Beta blocker, non-dihydropyridine Ca channel antagonist

 - Cardioversion in case of hemodynamically unstable state

- **Anticoagulation**

- **Sinus rhythm conversion**

 - : Electrical cardioversion in case of hemodynamically unstable state

 - Pharmacological cardioversion – amiodarone, dronedarone, flecainide,

January et al., JACC. 2014; 64(21), 2246-80

Anticoagulation therapy

- 심방세동 환자에서 뇌졸중 발생은 5배 증가
- Non-valvular A-fib을 가진 환자에서 뇌졸중과 전신 혈전색적증을 예방하기 위해 항응고 요법 시행
- Vt K antagonist anticoagulant (warfarin) - INR 2~3 유지
- Novel Oral Anticoagulants
- Stroke 위험성 사정: CHA₂DS₂-VASc score ≥ 1 에서 항응고 요법을 권장
- 출혈 위험성 사정

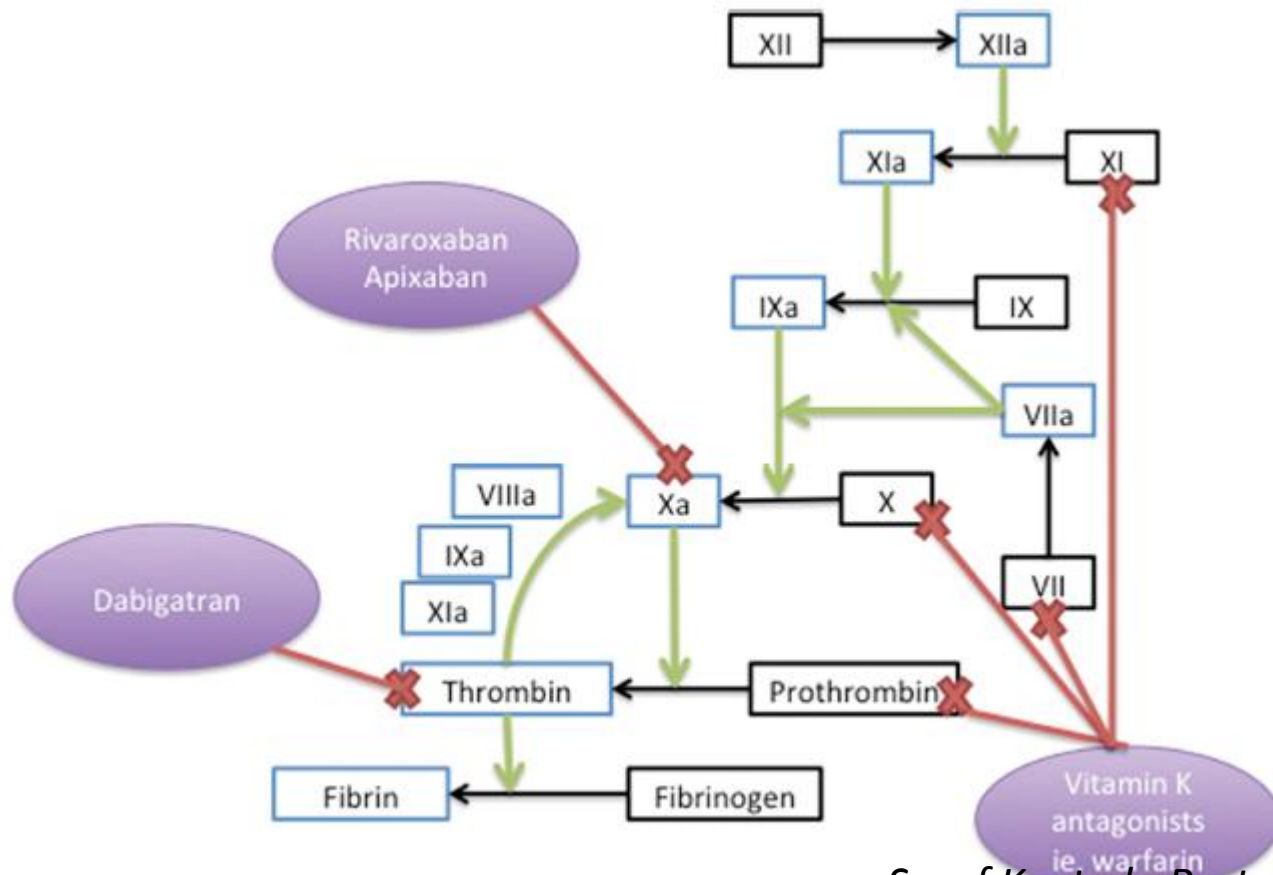
CHA₂DS₂-VASc score

Table 1. The CHA₂DS₂-VASc score

Letter	Risk factor	Score
C	Congestive heart failure/LV dysfunction	1
H	Hypertension	1
A ₂	Age ≥75	2
D	Diabetes mellitus	1
S ₂	Stroke/TIA/thrombo-embolism	2
V	Vascular disease*	1
A	Age 65–74	1
S	Sex category (i.e., female sex)	1
	Maximum score	9

Jung, BC et al., Korean Circ J. 2015; 45(1): 9-19

Action of novel oral anticoagulants



Saraf K, et al., Postgrad Med J. 2014; 90: 520-528

NOAC (novel oral anticoagulants)

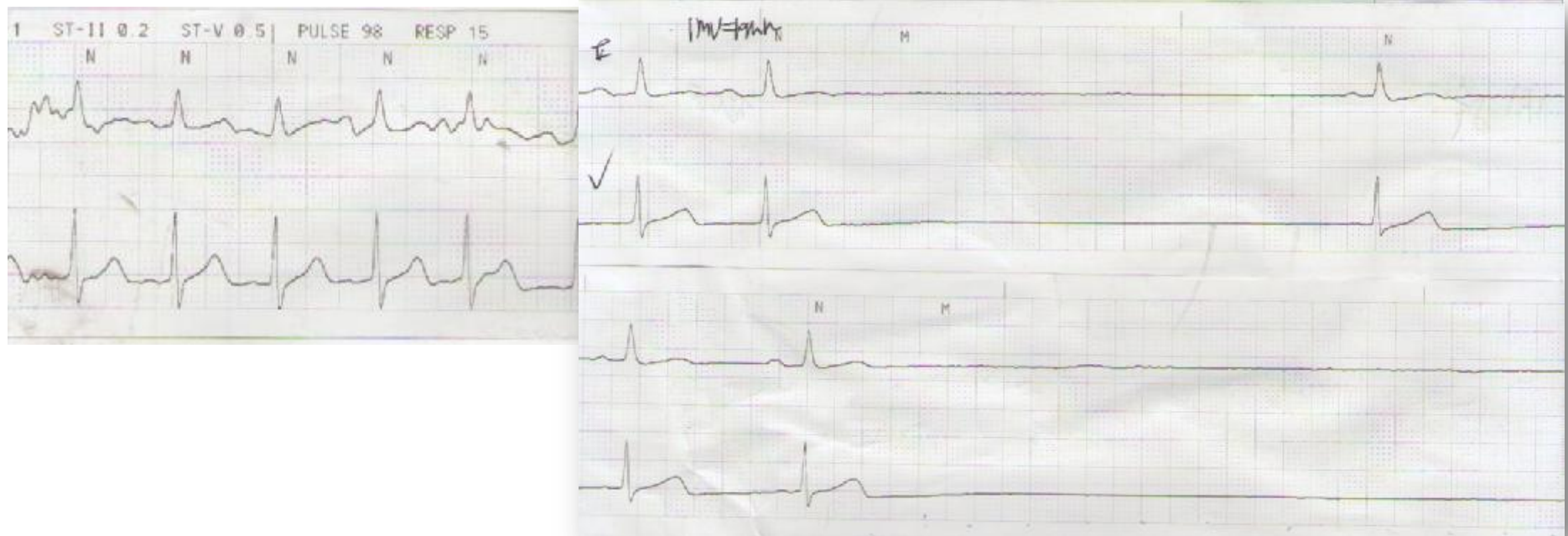- In place of warfarin in patients requiring anticoagulation therapy who have hypersensitivity or contraindication against warfarin, cannot maintain optimal INR range, or have cerebral hemorrhage despite adequate INR level therapy
- Not recommended in patients with stable anticoagulation control without bleeding
- Not recommended in patients with severe renal dysfunction

CASE 2

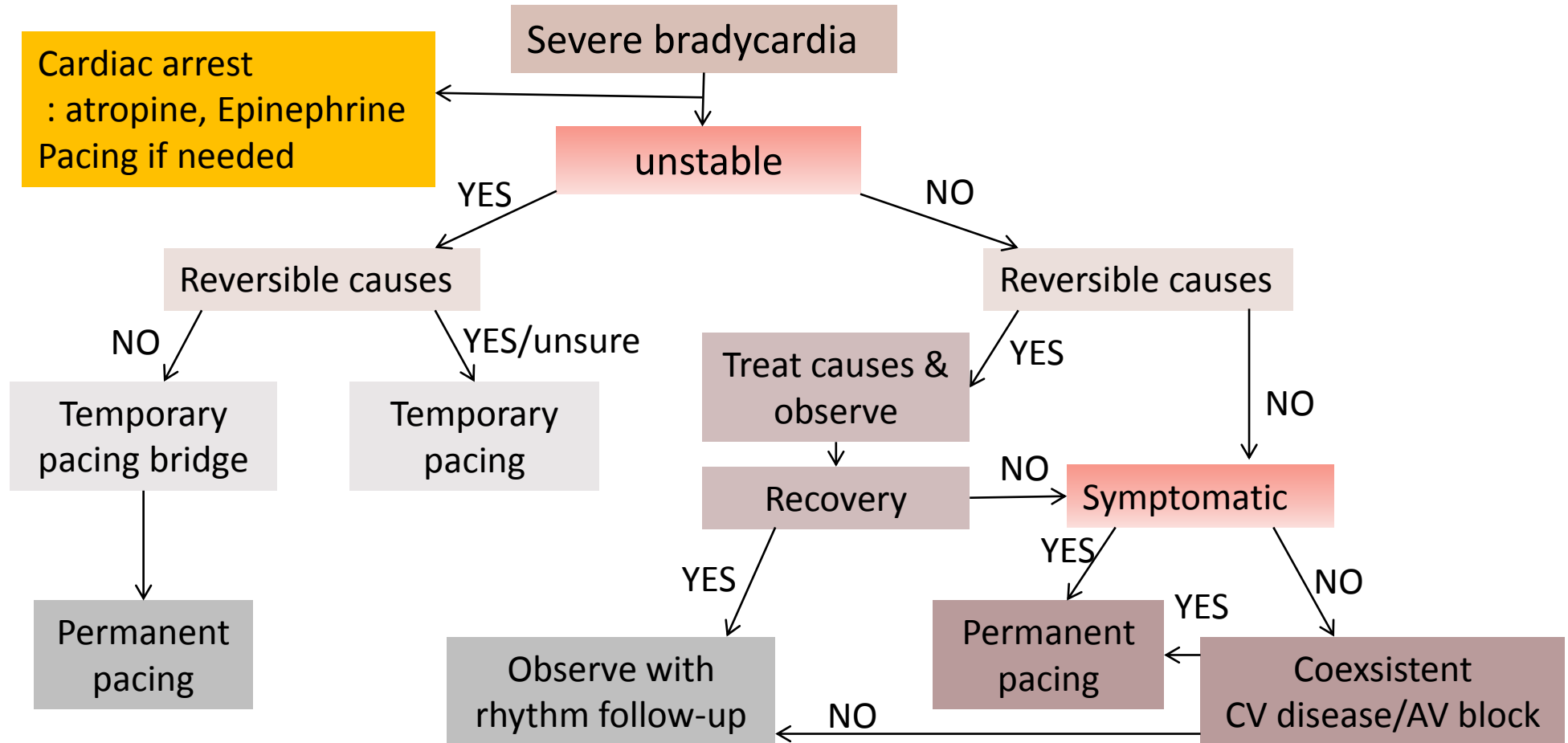
F/75Y

Aortic stenosis로 aortic valve replacement 시행 후 ICU care

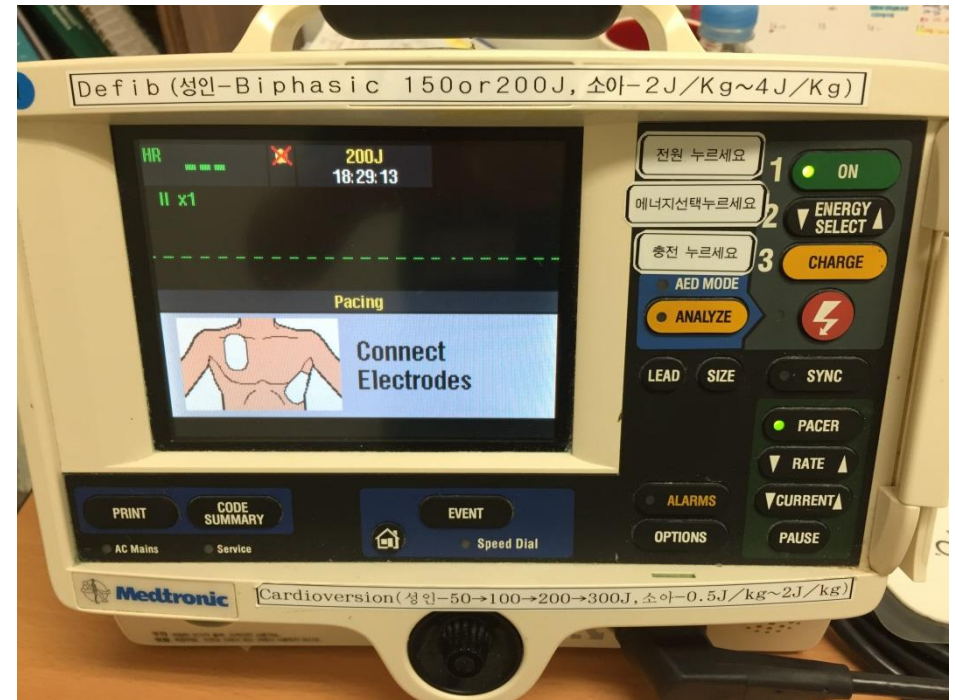
POD # 0



Management of bradyarrhythmia



Transcutaneous pacing (External pacing)

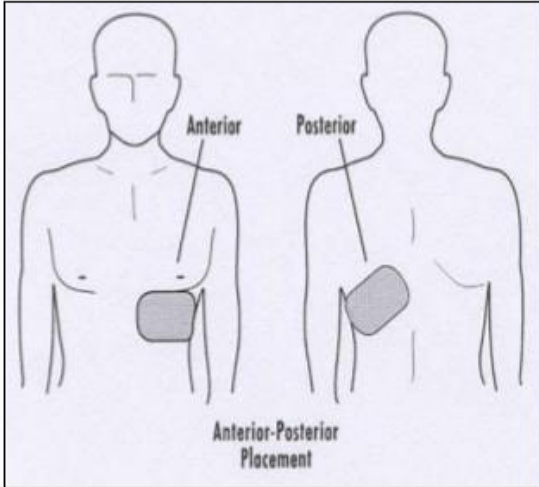


Paddle position


Paddle Placement

Anterior-Posterior

- One paddle on sternum and the other on the left infra-scapular region

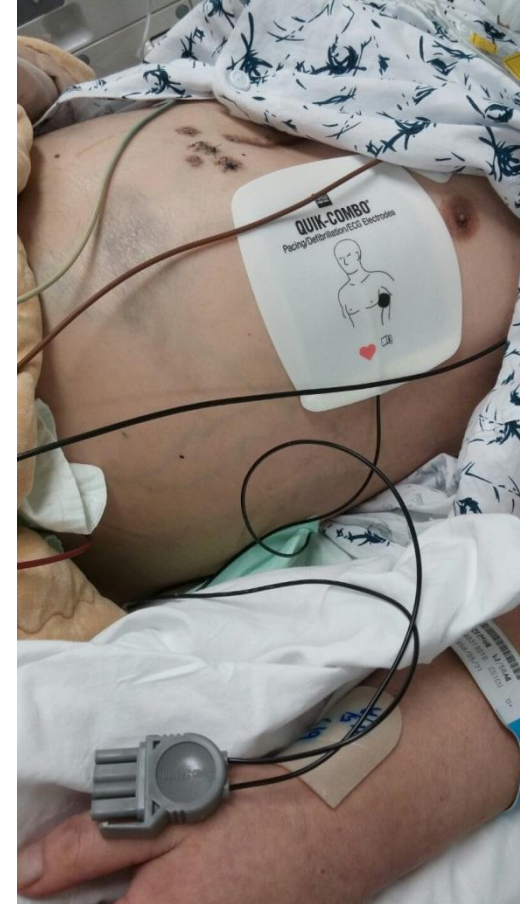

The diagram shows two human silhouettes. The left silhouette is labeled 'Anterior' and shows a grey rectangular paddle placed on the sternum. The right silhouette is labeled 'Posterior' and shows a grey rectangular paddle placed on the left infra-scapular region. Below the silhouettes, the text 'Anterior-Posterior Placement' is written.



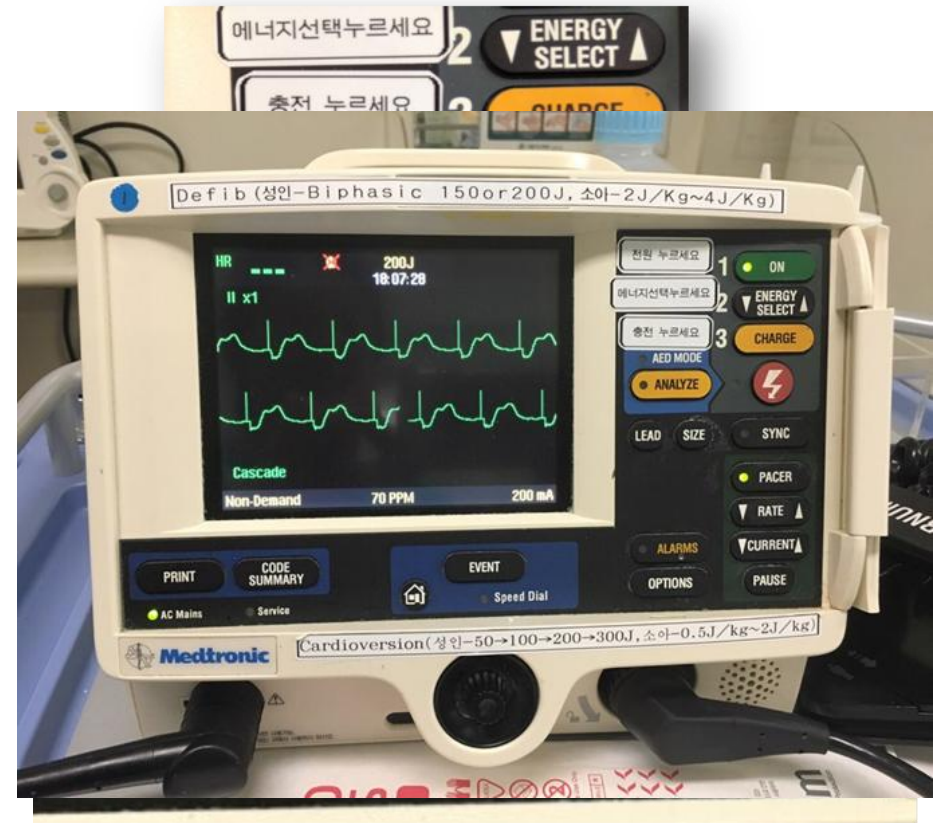Two green ovals represent the chest area. The left oval shows a red heart with a vertical black line passing through its center, representing the sternum. The right oval shows a red heart with a grey rectangular paddle placed on the left side, representing the infra-scapular region.

NGOJO



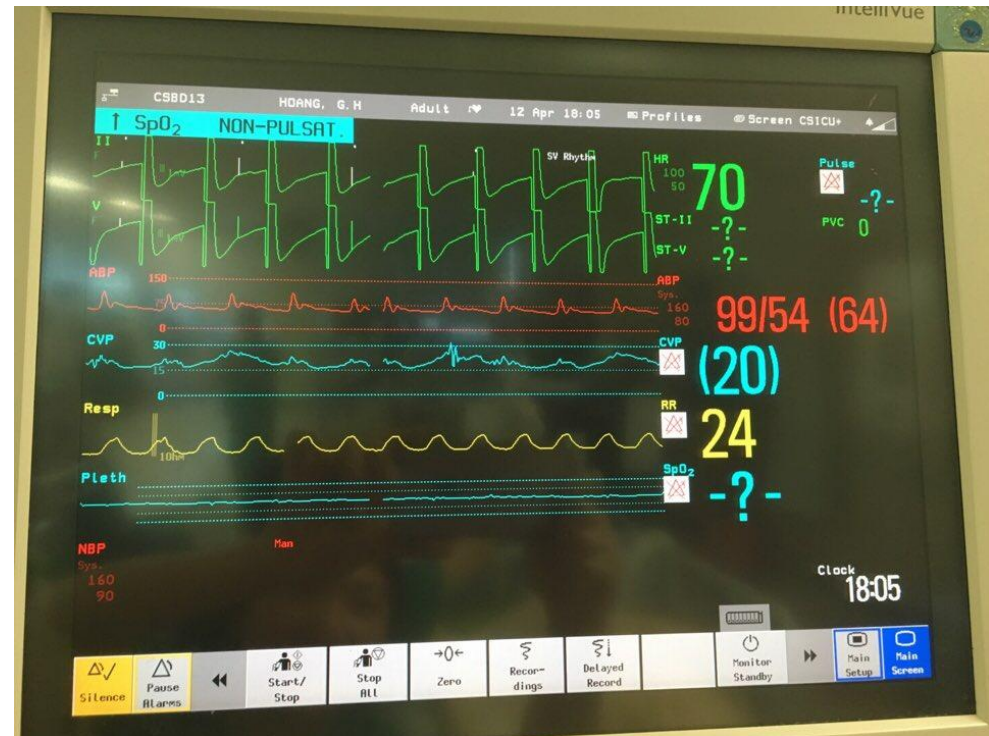External pacing ON

- Pacer ON
- Initial pacing rate 70-80bpm
- Current is increased by an additional 10mA above capture threshold (40-80mA)
- Administer analgesia/sedation for patient's comfort



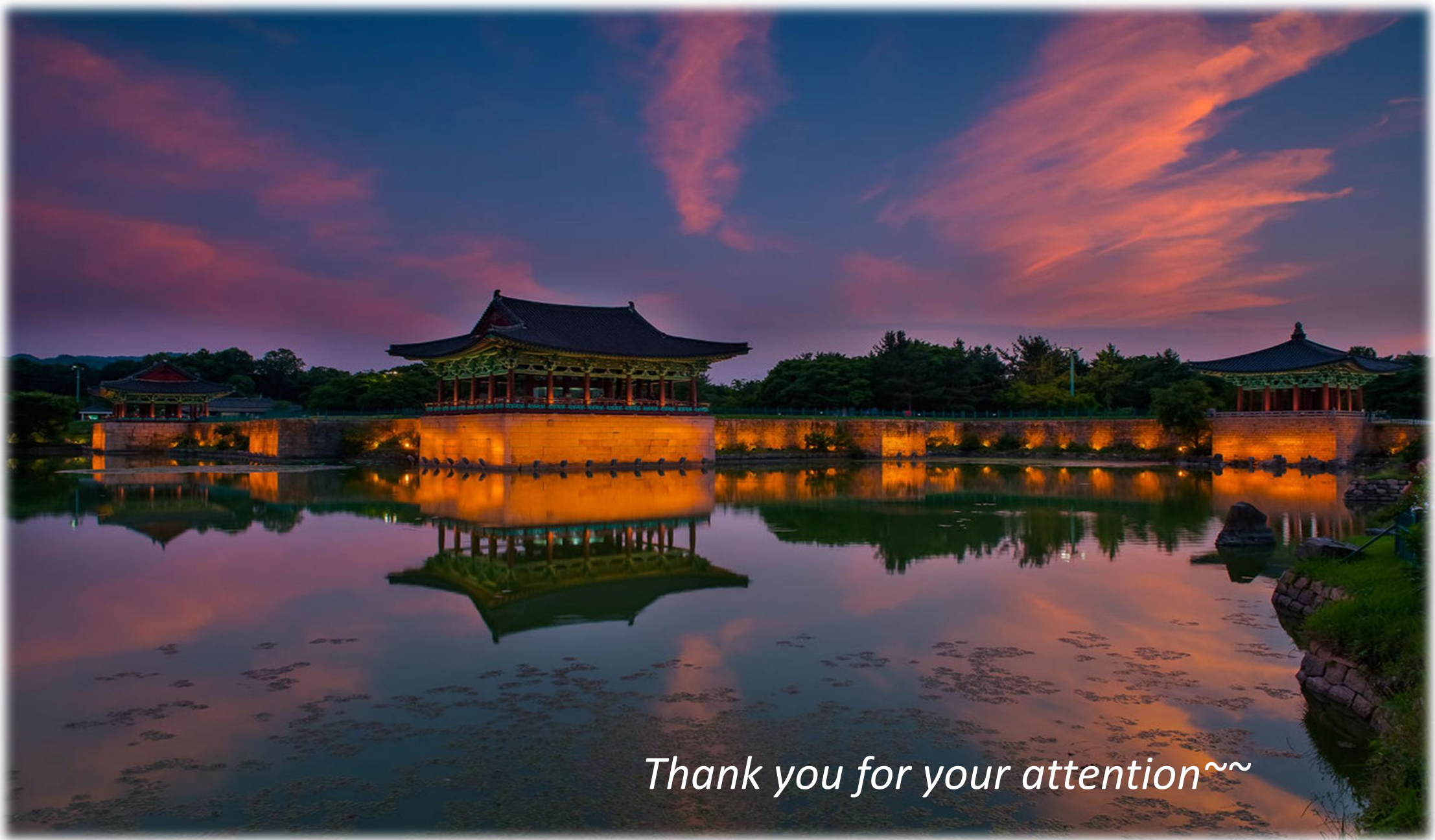Mechanical contraction

- Electrical activity
 - > Mechanical contraction
- Adequate capture
 - : palpation of artery pulse
 - arterial waveform
- Check skin burns and tissue damage



Summary

- Completely harmless or life-threatening arrhythmia
- **History and electrocardiography**
- Atrial fibrillation in patients with pulmonary diseases such as pulmonary thromboembolism, COPD or thyroid disease
- Symptom based management: hemodynamic compromise



Thank you for your attention~~